Acta Odontologica Scandinavica

ISSN: 0001-6357 (Print) 1502-3850 (Online) Journal homepage: http://www.tandfonline.com/loi/iode20

Effect of intraosseous injection versus inferior alveolar nerve block as primary pulpal anaesthesia of mandibular posterior teeth with symptomatic irreversible pulpitis: a prospective randomized clinical trial

Alireza Farhad, Hamid Razavian & Maryam Shafiee

To cite this article: Alireza Farhad, Hamid Razavian & Maryam Shafiee (2018): Effect of intraosseous injection versus inferior alveolar nerve block as primary pulpal anaesthesia of mandibular posterior teeth with symptomatic irreversible pulpitis: a prospective randomized clinical trial , Acta Odontologica Scandinavica, DOI: 10.1080/00016357.2018.1428826

To link to this article: https://doi.org/10.1080/00016357.2018.1428826

Published online: 27 Jan 2018.

ACTA ODONTOLOGICA SCANDINAVICA, 2018
https://doi.org/10.1080/00016357.2018.1428826

Taylor & Francis
Taylor & Francis Group

ORIGINAL ARTICLE

Effect of intraosseous injection versus inferior alveolar nerve block as primary pulpal anaesthesia of mandibular posterior teeth with symptomatic irreversible pulpitis: a prospective randomized clinical trial

Alireza Farhad[a], Hamid Razavian[a] and Maryam Shafiee[b]

[a]Dental Research Center, Department of Endodontics, School of Dentistry, Isfahan University of Medical Sciences, Isfahan, Iran; [b]Department of Endodontics, School of Dentistry, Isfahan University of Medical Sciences, Isfahan, Iran

ABSTRACT

Objective: This study sought to assess the success rate, effect on blood pressure, and pain of intraosseous injection (IO) and inferior alveolar nerve block (IANB) for pulpal anaesthesia of mandibular posterior teeth with symptomatic irreversible pulpitis as the primary anaesthetic technique.

Materials and methods: This randomized clinical trial (IRCT2013022712634N1) was conducted on 60 patients between 18 and 65 years suffering from symptomatic irreversible pulpitis of a mandibular posterior tooth. Patients were randomly divided into two groups. Group one received IO while group two received IANB with 3% mepivacaine. After anaesthetic injection, success rate of pulpal anaesthesia was assessed by pulp testing in the two groups. Systolic and diastolic blood pressures of patients were compared before and after the anaesthetic injections. Level of pain during injection was scored using a visual analogue scale. The data were analyzed using SPSS version 20, *t*-test and chi square test at $p = .05$ level of significance.

Results: Success rate of IO (56.7%) was significantly higher than that of IANB (23.3%) ($p = .008$). There was no significant difference in pain during anaesthetic injection ($p = .304$) or change in systolic ($p = .80$) and diastolic ($p = .28$) blood pressures following injection between the two techniques.

Conclusions: IO had a higher success rate than IANB for pulpal anaesthesia of mandibular posterior teeth with symptomatic irreversible pulpitis. Neither technique provided profound pulpal anaesthesia.

ARTICLE HISTORY
Received 3 August 2017
Revised 3 December 2017
Accepted 7 January 2018

KEYWORDS
Anaesthesia; inferior alveolar nerve block; intraosseous; mandible; pulpitis

Introduction

Achieving efficient pulpal anaesthesia is the first step for a successful endodontic treatment. Inadequate depth of anaesthesia prolongs the treatment time and creates stress in both clinician and patient. It can lower the quality of treatment and decrease patient cooperation as well. Thus, clinicians must adopt the most efficient method to achieve adequate depth of anaesthesia [1]. Inferior alveolar nerve block (IANB) is commonly performed to anesthetize the mandibular teeth [2]. However, the success of this technique is unpredictable particularly in teeth with symptomatic irreversible pulpitis [3]. The success rate of IANB in anesthetizing teeth with irreversible pulpitis has been reported to be 19–56% [4–8]. To overcome this problem, supplemental anaesthetic techniques including the periodontal ligament, intraosseous (IO), intrapulpal and sub-mylohyoid injections are recommended [9].

Intraosseous injection refers to penetrating the cortical bone adjacent to the root of the respective tooth. After penetration, a short needle is inserted into the site and anaesthetic agent is directly injected into the cancellous bone between the buccal and lingual cortices. Highly porous nature of the cancellous bone allows fast diffusion of the anaesthetic agent, and a deep state of anaesthesia is rapidly achieved as such [1,10]. At first, IO was administered as a supplemental anaesthetic technique to IANB particularly in cases of symptomatic irreversible pulpitis. A success rate of 71–98% has been reported for IO supplemental technique in teeth with irreversible pulpitis [4,5,11–13]. Advances in the commercially available products and devices for this purpose have increased the popularity of this technique and it is even attempted as the primary anaesthetic technique by many clinicians [1,10,14]. Previous studies have reported prompt onset and short duration of anaesthesia in this technique [1,14]. Moreover, IO claims to be simple, quick and comfortable [1].

Considering the importance of achieving adequate depth of anaesthesia in dental treatments as well as the current limitations of conventional anaesthetic techniques, finding an easily applicable anaesthetic technique with high predictability is of utmost importance. As mentioned earlier, IANB cannot provide adequate depth of anaesthesia in many cases. However, IO can be a successful alternative as a primary anaesthetic technique for achieving adequate depth of anaesthesia in teeth with symptomatic irreversible pulpitis. There is limited evidence regarding the efficacy of IO as a primary anaesthetic technique for teeth with symptomatic irreversible pulpitis and some concerns exist regarding the increase in blood pressure and level of pain during IO.

CONTACT Maryam Shafiee marymahsash@gmail.com Department of Endodontics, School of Dentistry, Isfahan University of Medical Sciences, Isfahan, Iran

The results of previous studies on the success rate, side effects and complications of IO technique are somehow controversial [1,9,10,15,16]. Thus, this study aimed to assess and compare the success rate, effect on systolic and diastolic blood pressures, and level of injection pain of IO and IANB as the primary anaesthetic technique for pulpal anaesthesia of mandibular posterior teeth with symptomatic irreversible pulpitis.

Materials and methods

This prospective randomized clinical trial was approved in the ethics committee of Isfahan University of Medical Sciences (#391473) and registered in www.irct.ir (IRCT2013022712634N1). Sample size analysis required 30 patients in each group to detect a difference of ±30% points in the success rate of anaesthesia with a power of more than 0.80 and a two-sided alpha risk of 0.05. A total of 60 patients presenting to a dental clinic with a mandibular posterior tooth (first or second molar or second premolar) with symptomatic irreversible pulpitis were selected. Patients included 30 males and 30 females between 18 and 65 years, who were recruited after signing written informed consent forms. Patients who were allergic to anaesthetic agents and sulphites, had a history of systemic conditions including high blood pressure, were taking analgesics or medications that might interfere with anaesthetic assessment, were pregnant, had an active pathosis in the site of injection, and were unwilling to participate were excluded.

Endo Ice (Hygienic Corp., Akron, OH) was used for diagnosis of symptomatic irreversible pulpitis after isolating the affected tooth with cotton rolls [1,4,8,10–12]. Patients expressed the level of pain experienced using Heft-Parker visual analogue scale (VAS).This is a psychometric response scale used to measure subjective characteristics along a continuous line between two end-points. Score zero indicated no pain, scores 1–54 indicated mild pain, scores 55–113 indicated moderate pain and scores 114–170 indicated severe pain [17]. Patients reporting moderate and severe lingering pain to cold testing, diagnosed with symptomatic irreversible pulpitis, were included. Diagnosis was made by a single operator (trained post-graduate endodontic student) to prevent bias in establishing the correct pulp diagnosis. Patients with no response to cold testing or periradicular pathosis (other than a widened periodontal ligament) were excluded from the study [4,8,10–12].

Assigned random numbers was used to randomly divide the patients into two equal groups of 30. Group one received IO while group two received IANB prior to endodontic treatment. To prevent bias, all anaesthetic injections were performed by the same endodontist (HR). Electric pulp tests were carried out by a single operator (trained post-graduate endodontic student).

To administer IO, first the alveolar mucosa adjacent to the site of injection was anesthetized with supraperiosteal infiltration anaesthesia using 0.6 mL of 3% mepivacaine (Scandinibsa 3%, Lica de vall, Barcelona, Spain). Five minutes later, success of soft tissue anaesthesia was assessed by probing the tissue. If the patient felt pain, an additional 0.3 mL of 3% mepivacaine was administered. Patients were in a reclining position during IO. Next, the site of IO was determined. For this purpose, a hypothetical horizontal line was drawn passing the buccal gingival margins of the first and second molars. Another hypothetical vertical line was also drawn passing through the centre of the distal papilla of the respective tooth. The injection point for IO was approximately 2 mm below the intersection of the mentioned two lines in attached gingiva. Radiographs were used to evaluate root proximity at the injection site. The X-tip guide sleeve (Dentsply Maillefer Co., Tulsa, OK) was locked in the drill and the perforator was inserted into the attached gingiva until bone was contacted. With the drill at 90° angle relative to the bone, slow-speed handpiece was guided into the bone using a gentle pecking motion. The handpiece had to be operating during the entire bone perforation procedure in order to prevent locking and subsequent fracture of device in bone. The guide sleeve was then detached from the drill and remained at the site. The tip of a 27-gauge short needle was bent for 60–80°. A standard syringe was held as gripping a pen, the needle tip was guided into the guiding sleeve and 1.8 mL of 3% mepivacaine was injected into bone within 2 min. If resistance was sensed during injection, the needle was rotated a quarter turn and injection was attempted again. After termination of injection, the guide sleeve was removed by a haemostat.

For IANB, the standard technique was performed [2]. A 27-gauge long needle was used to administer 1.8 mL of 3% mepivacaine within 2 min. If lip anaesthesia did not occur within 15 min after IANB, the technique of injection was assumed to be incorrect and the patient was excluded and replaced with another patient.

Four minutes after the injection, response to electric pulp test was assessed in both groups [1]. Baseline readings were recorded before anaesthetic injection. The contralateral tooth was used as negative control. No response to electric pulp test (80 reading) for two consecutive cycles with four-minute intervals indicated pulpal anaesthesia. If negative response to electric pulp test did not occur after 20 min of injection, anaesthesia was assumed to be a failure.

The instructions to each subject on how to rate the pain during injection was given by HR before each injection. After the injection, level of pain of patients during injection was assessed using a VAS. Systolic and diastolic blood pressures of patients in the two groups, ten minutes before and immediately after anaesthetic injection, were measured by a single operator (trained post-graduate endodontic student) using a digital device (CAS Medical Systems, Inc., Branford, CT). The data were analyzed using SPSS software version 20 (IBM Corporation, Armonk, NY), *t*-test and chi square test at $p = .05$ level of significance.

Results

The patients enrolled for this clinical trial are presented on a flow diagram (Figure 1). A total of 60 patients with a mean age of 31 ± 10 years participated in this study. Distribution of

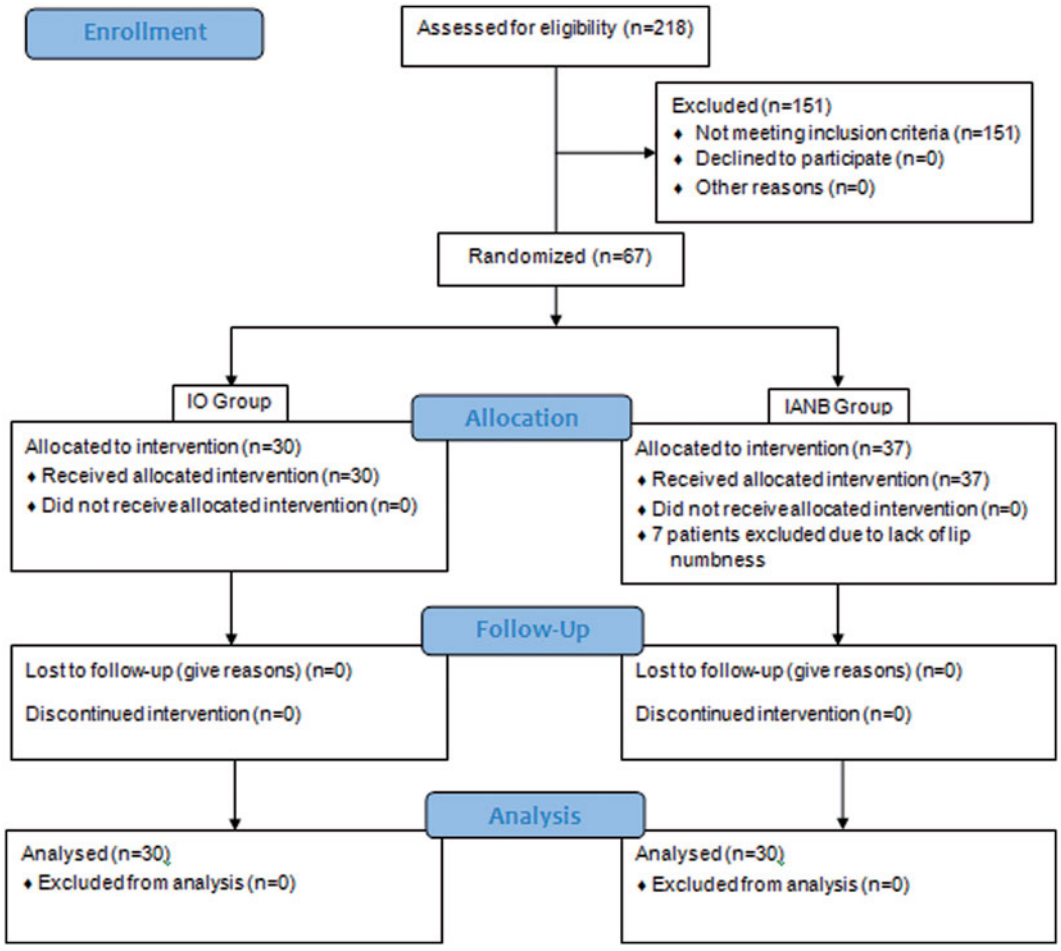

Figure 1. CONSORT flow diagram.

Table 1. Distribution of teeth in the intraosseous injection and inferior alveolar nerve block groups.

Tooth	Intraosseous injection, *n*(%)	Inferior alveolar nerve block, *n*(%)
Second premolar	3 (10)	5 (16.7)
First molar	23 (76.7)	21 (70)
Second molar	4 (13.3)	4 (13.3)

Table 2. Baseline variables for the intraosseous injection and inferior alveolar nerve block groups.

Variables	Intraosseous injection	Inferior alveolar nerve block	*p* value[a]
Total subjects	30	30	
Age (years)	18–48	18–64	.866
Sex	17 women 13 men	19 women 11 men	.598
Initial pain[b]	107 (31.08)	103 (29.75)	.604

[a]There were no significant differences between the two groups ($p > .05$).
[b]Mean (standard deviation), Heft–Parker visual analogue scale ratings.

teeth for IO and IANB groups is presented in Table 1. Independent *t*-test and chi square test found no significant difference between the two groups in terms of the mean age, sex, or initial pain (Table 2). Success rate was 56.7% in IO and 23.3% in IANB groups. Chi square test showed that the difference in this regard between the two groups was statistically significant ($p = .008$). The mean pain score during injection was 48 ± 29.0 in IO and 39 ± 35.3 in IANB groups.

Table 3. Mean (standard deviation) changes in systolic and diastolic blood pressures in the two groups.

Anaesthetic technique	Mean change in systolic blood pressure	Mean change in diastolic blood pressure
Intraosseous injection	0.34 (0.67)	0.27 (0.67)
Inferior alveolar nerve block	0.39 (0.33)	0.48 (0.48)

Independent *t*-test found no significant difference in pain score between the two groups ($p = .304$). The mean changes in systolic and diastolic blood pressures in the two groups are shown in Table 3. Independent *t*-test found no significant difference in the mean change of systolic ($p = .80$) and diastolic ($p = .28$) blood pressures between the two groups.

Discussion

Pulpal anaesthesia of teeth with hyperalgesia especially mandibular posterior teeth can be challenging for clinicians. The lower success rates in patients with symptomatic irreversible pulpitis may be due to the following factors: anatomical variations such as cross innervation and accessory innervation [18]; cytokines and chemokines induce the inflammatory activation and sensitization of nociceptive neurons [19]; resistance of tetrodotoxin-resistant sodium channels to the action

of local anaesthetics [20]; and anxious, apprehensive patients often have lowered pain threshold.

The success rate of IANB for pulpal anaesthesia of mandibular posterior teeth has been reported to be 55–70% [21]. This success rate decrease noticeably in acutely inflamed mandibular posterior teeth. On the other hand, IO has been reported to be a successful supplemental technique in anaesthesia of such teeth [1]. Reisman et al. [5] reported the success rate of IANB for anaesthesia of mandibular posterior teeth with irreversible pulpitis to be 25% and emphasized the need for administration of supplemental anaesthetic injections. They stated that the first supplemental IO of 3% mepivacaine increased the success rate of anaesthesia to 80% and the second supplemental IO of 3% mepivacaine further improved the success rate to 98%. Guglielmo et al. [22] concluded that IANB in conjunction with IO of 2% lidocaine with 1:100,000 epinephrine or 2% mepivacaine with 1:20,000 levonordefrin significantly increased anaesthetic efficacy in first molars and second premolars. Similarly, other reports have found increased success rates for supplemental IO in irreversibly inflamed pulps [4,11–13]. The aforementioned findings provide support for the potential use of IO as a primary technique to achieve predictable pulpal anaesthesia. The results of previous studies indicate that IO can provide pulpal anaesthesia in noninflamed teeth as a primary technique [14,23]. Remmers et al. [1] reported that the success rate of pulpal anaesthesia of mandibular posterior teeth with symptomatic pulpitis was 60% with IANB and 87% with IO as the primary anaesthetic technique using 2% lidocaine with 1:100,000 epinephrine. Pereira et al. [24] showed high IO anaesthetic efficacy of 4% articaine with 1:100,000 (96.8%) and 1:200,000 (93.1%) epinephrine in symptomatic irreversible pulpitis of mandibular molars. The success rate of IO of 3% mepivacaine in the current study was 56.7%, which was significantly more than IANB. This suggests that primary IO anaesthesia may be a useful technique in mandibular posterior teeth with symptomatic irreversible pulpitis. However, neither technique provided predictable profound pulpal anaesthesia. This indicates that, based on the results of this study, supplemental anaesthetic protocols are needed for both techniques to achieve the desired pulpal anaesthesia in such cases. The difference in primary IO success rates between the current study and previous results may be explained by use of different systems for IO, differences in type and volume of anaesthetic agents used, variable pain threshold of patients, differences in the severity of inflammation, anatomical variations and inter-individual and interracial differences.

In general, IO as the primary anaesthetic technique has some advantages compared to IANB. It has minimal lingering numbness of lips, does not cause anaesthesia of the tongue or tissue hematoma, is fast-acting and is atraumatic [1,2,14]. The duration of anaesthesia is limited because of the vascularity of the cancellous bone [1]. However, this limited duration of anaesthesia still allows for the problematic parts (access and initial instrumentation) of endodontic treatment in symptomatic teeth to be completed before the anaesthesia renders ineffective. Other possible side effects and complications of IO include palpitation, pain during and after bone perforation and traumatizing the lingual cortex of bone and roots [25]. Palpitation often occurs when anaesthetic agents containing a vasoconstrictor are administered. Contraindications of IO include periodontal disease, acute periapical infection, root fusion, difficult perforation of cortex due to high thickness, developing teeth, proximity to vital structure, and presence of inadequate volume of cancellous bone in the area [18].

The mandibular cancellous bone is a well-vascularized tissue, which could rapidly absorb anaesthetic agents causing cardiovascular changes [16,23]. Pereira et al. [24] compared the effects of IO of 4% articaine with 1:100,000 and 1:200,000 epinephrine on the cardiovascular system and indicated that both had minimal cardiovascular complications. They concluded that slow injection of anaesthetic agents decreased their adverse effects on the cardiovascular parameters including the heart rate and systolic and diastolic blood pressures. Coggins et al. [23] showed that 78% of patients experienced an increase in heart rate after IO of 2% lidocaine with 1:100,000 epinephrine. Replogle et al. [15] reported that 67% of the subjects experienced an increase in heart rate with IO of 2% lidocaine with 1:100,000 epinephrine while there was no significant increase in heart rate in subjects receiving 3% mepivacaine. They also found no significant differences in mean systolic and diastolic blood pressure values between the two anaesthetic solutions. However, another report indicated that rapid IO of 2% lidocaine with 1:80,000 epinephrine increased the blood pressure [16].The results of the current study showed that the mean change in systolic and diastolic blood pressures is positive for both IO and IANB groups, which indicates that both groups had a net increase in systolic and diastolic blood pressures after the injections. However, there was no significant difference in terms of mean changes in systolic and diastolic blood pressures between the two types of anaesthetic techniques, which is in accordance with the findings of other reports [15,24]. Taken together, it seems reasonable to assume that the slow injection of anaesthetic agent without vasoconstrictor can decrease the severity of cardiovascular side effects during IO. Although lidocaine is the gold standard for local anaesthesia, mepivacaine was used in the current study. By doing so, we intended to control the confounding effect of epinephrine on heart rate and blood pressure and the anaesthetic efficacy of mepivacaine as an alternative to lidocaine was also evaluated.

One of the important aspects of any primary anaesthetic technique is its pain during injection. This is especially true for patients in pain and stress from acutely inflamed teeth. McCartney et al. [26] reported moderate to severe pain during IANB in 57–89% of the patients. Gallatin et al. [27] showed that perforation, needle insertion and anaesthetic solution deposition resulted in 24–25%, 5–10% and 22–32% incidence of moderate pain during IO, respectively. Other studies have indicated 0–7% incidence of moderate pain for perforation and 2–15% incidence of moderate pain and 0–2% incidence of severe pain for anaesthetic solution deposition at the mandibular first molar site during IO [23,28]. However, the present study showed that the mean pain score during injection was in the mild category for IO

and IANB with no significant difference. The current study considered the injection process as a single phase instead of dividing it to separate steps. This may be the reason for different injection pain values obtained in this study compared to previous studies. Other reasons may include operator technique, different IO systems and differences in patient population.

In the present study, all teeth in both groups had moderate to severe VAS initial pain. Accordingly, baseline variables of patients (age, sex and initial pain) were not significantly different between the two groups. This means that these variables had no effect on the final outcome obtained. In addition, the efficacy of IO and IANB was assessed by measuring the responsiveness of the teeth to electric pulp tester. This was based on the results of Certosimo and Archer [29] in which the ability of the electric pulp tester was evaluated in measuring the level of local anaesthesia. They reported that the electric pulp tester can be a valuable tool in predicting anaesthetic problems in dentistry. Moreover, other clinical trials have used this technique to measure the effectiveness of local anaesthesia in symptomatic and normal teeth [1,10,22,24,30]. Nevertheless, in patients with symptomatic irreversible pulpitis, a negative electric pulp test response may not indicate profound pulpal anaesthesia during endodontic treatment [4]. This suggests that the actual success rates of the two techniques for the current study may be lower than the values obtained.

The clinical significance of the results of the present study should be viewed by considering its limitations. The use of electric pulp tester to measure the anaesthetic success may be a possible limitation of the current clinical trial. Hence, further investigations using pain during endodontic treatment as outcome measure are required to further elucidate this topic.

Conclusions

The results of the present study showed that IO had a higher success rate than IANB for pulpal anaesthesia of mandibular posterior teeth with symptomatic irreversible pulpitis. Neither technique provided profound pulpal anaesthesia. No significant difference was noted in pain during anaesthetic injection or change in systolic and diastolic blood pressures following injection between the two techniques.

Disclosure statement

The authors report no conflicts of interest.

Funding

This work was supported by Isfahan University of Medical Sciences, [grant no. 391473], Isfahan, Iran.

References

[1] Remmers T, Glickman G, Spears R, et al. The efficacy of IntraFlow intraosseous injection as a primary anaesthesia technique. J Endod. 2008;34:280–283.

[2] Malamed SF. Handbook of local anaesthesia. 5th ed. St Louis (MO): Mosby; 2004.

[3] Nusstein JM, Reader A, Drum M. Local anaesthesia strategies for the patient with a "hot" tooth. Dent Clin North Am. 2010; 54:237–247.

[4] Nusstein J, Reader A, Nist R, et al. Anaesthetic efficacy of the supplemental intraosseous injection of 2% lidocaine with 1:100,000 epinephrine in irreversible pulpitis. J Endod. 1998;24:487–491.

[5] Reisman D, Reader A, Nist R, et al. Anaesthetic efficacy of the supplemental intraosseous injection of 3% mepivacaine in irreversible pulpitis. Oral Surg Oral Med Oral Pathol Oral Radiol Endod. 1997;84:676–682.

[6] Cohen HP, Cha BY, Spangberg LS. Endodontic anaesthesia in mandibular molars: a clinical study. J Endod. 1993;19:370–373.

[7] Nusstein J, Reader A, Beck FM. Anaesthetic efficacy of different volumes of lidocaine with epinephrine for inferior alveolar nerve blocks. Gen Dent. 2002;50:372–375; quiz 376–377.

[8] Kennedy S, Reader A, Nusstein J, et al. The significance of needle deflection in success of the inferior alveolar nerve block in patients with irreversible pulpitis. J Endod. 2003;29:630–633.

[9] Moore PA, Cuddy MA, Cooke MR, et al. Periodontal ligament and intraosseous anaesthetic injection techniques: alternatives to mandibular nerve blocks. J Am Dent Assoc. 2011;142(Suppl 3):13s–18s.

[10] Razavian H, Kazemi S, Khazaei S, et al. X-tip intraosseous injection system as a primary anaesthesia for irreversible pulpitis of posterior mandibular teeth: a randomized clinical trial. Dent Res J. 2013;10:210–213.

[11] Bigby J, Reader A, Nusstein J, et al. Articaine for supplemental intraosseous anaesthesia in patients with irreversible pulpitis. J Endod. 2006;32:1044–1047.

[12] Nusstein J, Kennedy S, Reader A, et al. Anaesthetic efficacy of the supplemental X-tip intraosseous injection in patients with irreversible pulpitis. J Endod. 2003;29:724–728.

[13] Parente SA, Anderson RW, Herman WW, et al. Anaesthetic efficacy of the supplemental intraosseous injection for teeth with irreversible pulpitis. J Endod. 1998;24:826–828.

[14] Gallatin J, Reader A, Nusstein J, et al. A comparison of two intraosseous anaesthetic techniques in mandibular posterior teeth. J Am Dent Assoc. 2003;134:1476–1484.

[15] Replogle K, Reader A, Nist R, et al. Cardiovascular effects of intraosseous injections of 2 percent lidocaine with 1:100,000 epinephrine and 3 percent mepivacaine. J Am Dent Assoc. 1999;130: 649–657.

[16] Lilienthal B, Reynolds AK. Cardiovascular responses to intraosseous injections containing catecholamines. Oral Surg Oral Med Oral Pathol. 1975;40:574–583.

[17] Heft MW, Parker SR. An experimental basis for revising the graphic rating scale for pain. Pain. 1984;19:153–161.

[18] Hargreaves KM, Keiser K. Local anaesthetic failure in endodontics. Endodontic Topics. 2002;1:26–39.

[19] Modaresi J, Dianat O, Soluti A. Effect of pulp inflammation on nerve impulse quality with or without anaesthesia. J Endod. 2008;34:438–441.

[20] Roy ML, Narahashi T. Differential properties of tetrodotoxin-sensitive and tetrodotoxin-resistant sodium channels in rat dorsal root ganglion neurons. J Neurosci. 1992;12:2104–2111.

[21] Potocnik I, Bajrovic F. Failure of inferior alveolar nerve block in endodontics. Endod Dent Traumatol. 1999;15:247–251.

[22] Guglielmo A, Reader A, Nist R, et al. Anaesthetic efficacy and heart rate effects of the supplemental intraosseous injection of 2% mepivacaine with 1:20,000 levonordefrin. Oral Surg Oral Med Oral Pathol Oral Radiol Endod. 1999;87:284–293.

[23] Coggins R, Reader A, Nist R, et al. Anaesthetic efficacy of the intraosseous injection in maxillary and mandibular teeth. Oral Surg Oral Med Oral Pathol Oral Radiol Endod. 1996;81:634–641.

[24] Pereira LA, Groppo FC, Bergamaschi Cde C, et al. Articaine (4%) with epinephrine (1:100,000 or 1:200,000) in intraosseous injections in symptomatic irreversible pulpitis of mandibular

molars: anaesthetic efficacy and cardiovascular effects. Oral Surg Oral Med Oral Pathol Oral Radiol. 2013;116:e85–e91.

[25] Leonard MS. The efficacy of an intraosseous injection system of delivering local anaesthetic. J Am Dent Assoc. 1995;126:81–86.

[26] McCartney M, Reader A, Beck M. Injection pain of the inferior alveolar nerve block in patients with irreversible pulpitis. Oral Surg Oral Med Oral Pathol Oral Radiol Endod. 2007;104:571–575.

[27] Gallatin J, Nusstein J, Reader A, et al. A comparison of injection pain and postoperative pain of two intraosseous anaesthetic techniques. Anesth Prog. 2003;50:111–120.

[28] Replogle K, Reader A, Nist R, et al. Anaesthetic efficacy of the intraosseous injection of 2% lidocaine (1:100,000 epinephrine) and 3% mepivacaine in mandibular first molars. Oral Surg Oral Med Oral Pathol Oral Radiol Endod. 1997;83:30–37.

[29] Certosimo AJ, Archer RD. A clinical evaluation of the electric pulp tester as an indicator of local anaesthesia. Oper Dent. 1996;21:25–30.

[30] Goldberg S, Reader A, Drum M, et al. Comparison of the anaesthetic efficacy of the conventional inferior alveolar, Gow-Gates, and Vazirani-Akinosi techniques. J Endod. 2008;34:1306–1311.